



A Rare Case Of Congenital Foregut Cyst

¹Asayas Bosco Chandra Kumar*, ² M.L.Jagadeesan, ³M.Senthil Velan,⁴K.V.Maheswaran, ⁵S.Rajasekaran, ⁶K.Balagurunathan.

ABSTRACT

A congenital foregut cyst is a rare finding on a laparotomy. The incidence is not known. Here is a case operated and found to have a simple foregut cyst. The set back of this case is that a pre operative diagnosis with respect to investigation is not specific and conclusive.

KEY WORDS : Intra-Abdomen Cyst, Foregut Cysts, Congenital Cyst

Introduction

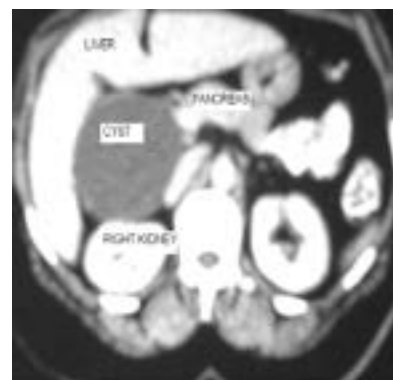Cyst is common findings in surgical practice. Cyst is defined as a fluid filled cavity usually clear fluid. And can be due to various etiology. The case report we present is a rare cyst of the foregut.

Case Report

A case of a middle age obese lady with recurrent upper abdomen pain for 2 years and was treated with antacids outside but no relief. No co-morbid conditions.

Good appetite, regular food and bowel habits. No significant menstrual history. On examination per abdomen was normal and clinical diagnosis was? Cholelithiasis / APD. And the investigation for the same done Upper GI scopy was normal which rule out the possibility of APD. USG of the abdomen showed probably cyst arising from the liver[1]. kidney – a cortical cyst. CECT abdomen was done. Which revealed a foregut cyst [2].

(Fig.No. 1) : CECT abdomen revealed a foregut cyst



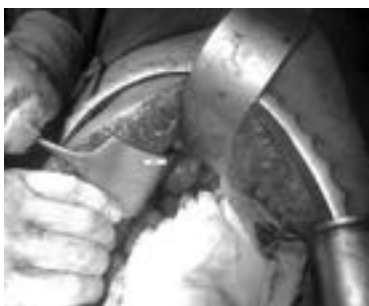¹Associate Professor,
^{2,3,4,5,6} Professor
Department of General Surgery,
Sri Lakshmi Narayana Institute of Medical Sciences, Puduchery.

*Corresponding Author

Dr. Asayas Bosco Chandra Kumar
Associate Professor of General Surgery,
Sri Lakshmi Narayana Institute of Medical Sciences, Puduchery.
E-mail ID : drasayas.surgeon@gmail.com
Mobile : 9159819500

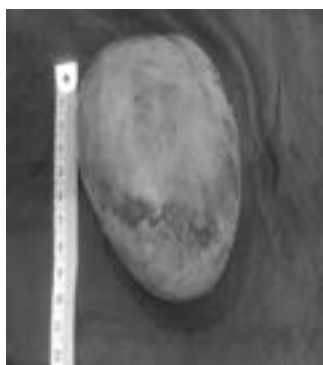
The cyst wall was clearly defined from the surrounding liver, kidney, IVC and the duodenum. CECT abdomen not revealed for the site of origin. Laparotomy planned for exploration and excision of the cyst. Laparotomy again showed a cyst in the subhepatic region and no attachment to the surrounding organs.

[Fig. No. 2] : Foregut cyst with surrounding organs



A smooth thin walled cyst measuring 10X8 cm in the subhepatic region lateral to the duodenum and the pancreas, superiorly and laterally liver, posterior and inferior relation to the kidney. The cyst wall was loosely adherent to all its relations. The cyst was enucleated

[Fig. No. 3 : Excised foregut cyst]



with finger dissection alone with minimal bleeding pericyst region.

Patient in the post-operative period was uneventful and sutures removed on post op day 7. And patient discharged and is on follow up.

Discussion

A very rare and interesting case we have operated usually bronchogenic cysts[3] are foregut-derived developmental anomalies most commonly encountered in the mediastinum and rarely in the abdomen or foregut. Intraabdominal cystic swellings are more common in the new born and children[4-5]. The etiology of cyst is suspected in the development of the diaphragm for the location[6].

This case is more of an incidentaloma in presentation and investigation. These cyst does not need extensive investigation like a PET[7] scan. Our case report is one of the rarest findings in the adult and only a few cases are reported in the literature. The case report highlight that a cyst in the foregut location has many surgically associated complications if the surgery is not executed well. So a proper meticulous surgical technique is required for the better outcome of the procedure. Some isolated report of sclerotherapy used for diaphragmatic mesothelial cysts in children[8]. But we had no expertise to do at our centre so sclerotherapy no planned for this patient.

Conclusion

A simple congenital be also a part of a differential diagnosis in an undiagnosed foregut cyst.

So a knowledge of the common differential diagnosis and rare diagnosis is useful for successful management of the patient.

References

1. Haap M, Seeger A, Haas CS, giant solitary hepatic cyst. *Liver int.* 2008;28:840.
2. Yang DM, Jung DH, Kim H. Retroperitoneal cystic masses: CT, clinical and pathological findings and literature review. *Radiographics.* 2004;24:353-365.
3. Liang MK, Yee HT, Song JW, Marks JL. Sub diaphragmatic bronchogenic cysts: a comprehensive review of the literature. *Am Surg.* 2005 Dec;71(12):1034-41

4. Rk raghupathy. At. Intraabdominal Cystic Swelling in Children— Laparoscopic Approach, Our Experience J Indian assoc pediater surg, 2003. Oct to Dec; vol.8
5. Reynolds M. Foregut cysts of the mediastinum in children and in adults. General Thoracic Surgery, 6th ed Pittsburgh, PA: Lippincott, Williams & Wilkins, 2004;2823–2829.
6. Mayer MP, Janzen J, Schweizer P. Intrathoracic and intraabdominal locations of a cystic benign tumor: congenital etiology due to embryological diaphragm development? *Pediatr Surg Int* 2004.
7. Miguel Hernandez Pampaloni and Aung Z. Win. International Prevalence and Characteristics of Incidentalomas Discovered by Whole Body FDG PETCT *Journal of Molecular Imaging*.1212; Volume 12; 6 p.
8. Akinci. diaphragmatic mesothelial cysts in children: radiologic findings and percutaneous ethanol sclerotherapy, *AJR*. October 2005: 185.